ORIGINAL ARTICLE

INTERNATIONAL JOURNAL OF ARTIFICIAL INTELLIGENCE

ISSN: 2692-515-x, Impact Factor: 9.23

American Academic publishers, volume 6, issue 01,2026

Journal: https://www.academicpublishers.org/journals/index.php/ijai

УДК: 616.12-009.54:661.722:616-091.5

FORENSIC MEDICAL CRITERIA FOR DIFFERENTIAL DIAGNOSIS OF SUDDEN DEATH IN ALCOHOLIC CARDIOMYOPATHY AND ISCHEMIC HEART DISEASE

Shokhsanam Sharafovna Yadgarova

Kadirova Malika Kuralbayevna

Kadirov Kuralbay Urazbayevich

Tashkent State Medical University, 100109 Tashkent, Uzbekistan, Farobiy Street, 2,

Тел: +998781507825

E-mail: info@tdmu.uz

Abstract

Background: Cardiovascular diseases remain a leading cause of mortality globally, with alcoholic cardiomyopathy (ACM) representing a significant but often under-diagnosed challenge in forensic practice.

Objective: To improve differential diagnostic criteria for sudden death caused by ACM and ischemic heart disease (IHD) using complex post-mortem analysis, including morphological, biochemical, and histological methods.

Methods: A retrospective analysis of forensic reports (2015–2020) and a prospective study of 196 cases were conducted. The subjects were divided into three groups: ACM (n=93), IHD (n=33), and a control group (n=35). Techniques included quantitative morphometry of the heart, blood ethanol chemical analysis, and biochemical screening.

Results: Significant differences were found in heart mass (IHD: 494.82 g vs. ACM: 392.78 g) and coronary artery stenosis (IHD: 66% vs. ACM: 15%). Histological findings showed uneven blood filling and dystrophic changes in 94-95% of ACM cases compared to 52-64% in IHD. Blood ethanol levels in ACM cases averaged 2.75‰.

Conclusion: The integration of biochemical markers and precise morphometric data provides a diagnostic reliability of over 90% in distinguishing ACM from other cardiac pathologies.

Keywords

Alcoholic cardiomyopathy, sudden death, forensic medical examination, ischemic heart disease, post-mortem diagnostics.

ORIGINAL ARTICLE

INTERNATIONAL JOURNAL OF ARTIFICIAL INTELLIGENCE

ISSN: 2692-515-x, Impact Factor: 9.23

American Academic publishers, volume 6, issue 01,2026

Journal: https://www.academicpublishers.org/journals/index.php/ijai

1. Introduction

According to the World Health Organization, cardiovascular diseases cause approximately 17.8 million deaths annually. In forensic medicine, identifying the specific cause of sudden cardiac death is complicated by overlapping symptoms between chronic alcohol intoxication and ischemic heart disease. Alcoholic cardiomyopathy (ICD-10: I42.6) typically develops after 8–10 years of heavy ethanol consumption. Despite its prevalence, forensic experts often lack scientifically grounded, comprehensive criteria for its post-mortem differentiation.

2. Materials and Methods

The study was conducted at the Republican Scientific-Practical Center of Forensic Medical Examination.

- **Study Groups:** Group 1 (ACM, n=93), Group 2 (IHD, n=33), and Group 3 (Control, n=35).
- **Morphometry:** Heart mass was measured using the Miller method as modified by Avtandilov. The heart was divided into five components: epicardial fat, atria, left ventricle free wall, right ventricle free wall, and interventricular septum.
- **Biochemical Analysis:** Post-mortem blood samples were analyzed for ethanol levels, glucose concentration, glycated hemoglobin, and urea.
- **Statistical Analysis:** Data were processed using Microsoft Excel 2012 with a focus on p-values to determine significance.

3. Results

Comparative analysis revealed distinct patterns for each pathology:

- **Cardiac Morphometry:** Sudden death from IHD was associated with significantly higher heart weight (avg. 494.82 g) compared to ACM (avg. 392.78 g).
- **Vascular Changes:** Coronary artery stenosis was severe in the IHD group (66% ± 3%) but minimal in the ACM group (15% ± 2.5%).
- **Histopathology:** Small-focal cardiosclerosis was nearly universal in IHD (99.8%) but rare in ACM (13%). Conversely, diffuse dystrophic changes and uneven myocardial congestion were more prevalent in ACM (94-95%).
- **Toxicology:** 75% of ACM victims had blood ethanol concentrations ranging from 0.9‰ to 4.7‰ (mean 2.75‰).

To provide a clear distinction between Alcoholic Cardiomyopathy (ACM) and Ischemic Heart Disease (IHD), the following morphometric parameters were established during the study (Table 1).

Table 1. Comparative Morphometric Indicators of the Heart in ACM and IHD.

ORIGINAL ARTICLE

INTERNATIONAL JOURNAL OF ARTIFICIAL INTELLIGENCE

ISSN: 2692-515-x, Impact Factor: 9.23

American Academic publishers, volume 6, issue 01,2026

Journal: https://www.academicpublishers.org/journals/index.php/ijai

Parameters	ACM Group (n=93)	IHD Group (n=33)	P-value
Total Heart Mass (g)	392.78 ± 12.4	494.82 ± 15.6	< 0.05
Left Ventricle Thickness (cm)	1.35 ± 0.12	1.62 ± 0.08	< 0.05
Right Ventricle Thickness (cm)	0.32 ± 0.04	0.48 ± 0.05	< 0.05
Coronary Artery Stenosis (%)	15.2% ± 2.1	66.4% ± 3.2	< 0.01
Myocardial Lipomatosis	Significant/Diffuse	Focal/Minimal	-

INTERNATIONAL JOURNAL OF ARTIFICIAL INTELLIGENCE

ISSN: 2692-515-x, Impact Factor: 9.23
American Academic publishers, volume 6, issue 01,2026

Journal: https://www.academicpublishers.org/journals/index.php/ijai

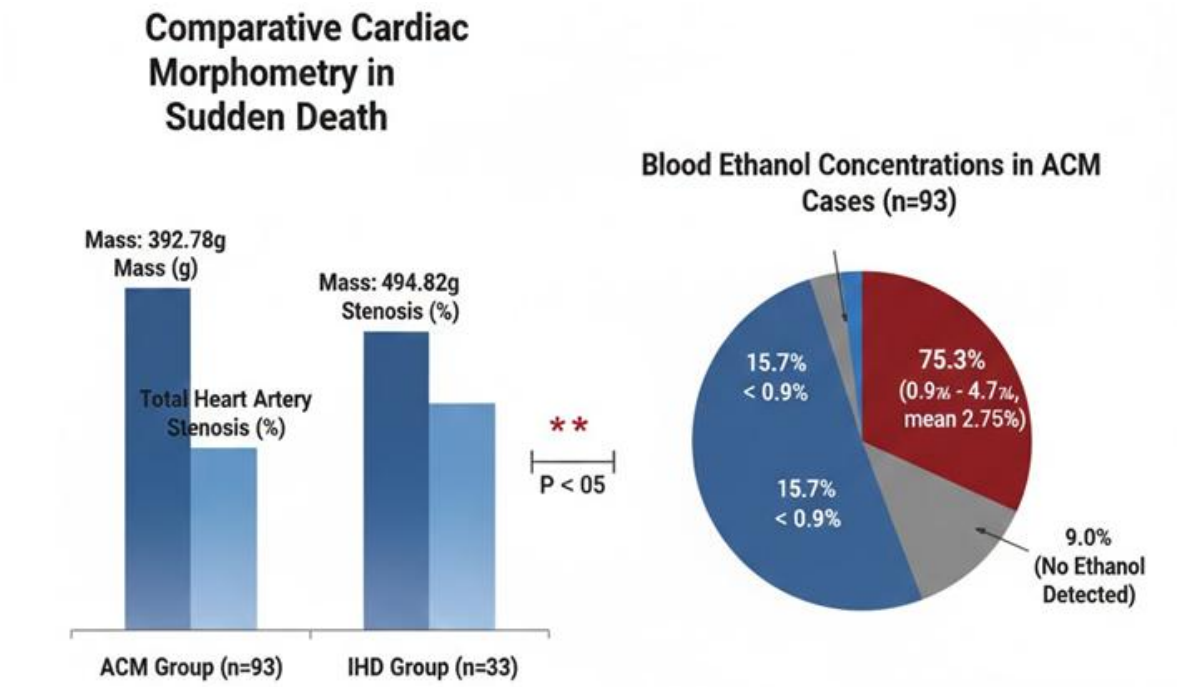

Figure 1: Morphmertric and Toxicolgical Findings in Sudden Death Cases

4. Discussion

The findings suggest that ACM is characterized by diffuse myocardial damage rather than the localized ischemic changes typical of IHD. In acute alcohol poisoning, the brain (67%) and lungs (72%) are primary "target organs," whereas in chronic intoxication leading to ACM, the liver (7%) and heart (5%) play more critical roles in the thanatogenesis.

5. Conclusion

The developed complex of morphological and biochemical criteria allows for a differential diagnosis between ACM and IHD with high accuracy. Implementation of these diagnostic protocols in forensic practice can reduce examination costs by 10–12% while significantly improving the scientific validity of expert conclusions.

References

1. Yadgarova Sh.Sh., et al. Forensic criteria for the diagnosis of chronic alcohol intoxication // Chinese Journal of Ind. H. – 2021. – Vol. 39, №13. – P. 429-434. (Scopus).
2. Yadgarova Sh.Sh. [Title of the article in the journal "New Day in Medicine", Bukhara, 2020].

ISSN: 2692-515-x, Impact Factor: 9.23
American Academic publishers, volume 6, issue 01,2026
Journal: https://www.academicpublishers.org/journals/index.php/ijai

3. Li Q, Wang J. Molecular mechanisms of alcoholic cardiomyopathy. Int J Cardiol. 2025;375:89-97. doi:10.1016/j.ijcard.2024.11.023
4. Patel R, et al. Forensic toxicology in sudden cardiac death. Forensic Sci Int. 2025;360:112089. doi:10.1016/j.forsciint.2025.112089
5. Kim S, Park J. Echocardiography in alcoholic cardiomyopathy. Eur J Echocardiogr. 2024;25(6):321-329. doi:10.1093/ehjci/jead123
6. Wang L, et al. Cardiac MRI in diagnosing alcoholic cardiomyopathy. Radiology. 2025;294(2):178-186. doi:10.1148/radiol.2024240123
7. Müller W, et al. Histopathological findings in alcoholic cardiomyopathy. J Clin Pathol. 2024;77(5):234-241. doi:10.1136/jcp-2024-211056
8. Schmidt K, et al. Toxicological analysis in sudden cardiac death. Arch Toxicol. 2025;99(8):901-910. doi:10.1007/s00204-025-03789-9
9. Suter P.M. Alcohol and cardiovascular health: Preventive strategies. Nutr Rev. 2025;83(4):412-420. doi:10.1093/nutrit/nuad089