ORIGINAL ARTICLE

INTERNATIONAL JOURNAL OF ARTIFICIAL INTELLIGENCE

ISSN: 2692-515-x, Impact Factor: 9.23

American Academic publishers, volume 6, issue 01,2026

Journal: https://www.academicpublishers.org/journals/index.php/ijai

STUDY OF PATHOMORPHOLOGICAL CHANGES IN THE PITUITARY GLAND IN SUDDEN CARDIAC DEATH USING SILVER NITRATE IMPREGNATION (18–59 AGE GROUPS)

Imomov Kh.M.
Mamataliyeva M.A.
Fazlitdinova R.S.
Ahmedova M.Sh.
Andijan State Medical Institute, Andijan, Uzbekistan

Introduction and Relevance of the Study

Sudden Cardiac Death (SCD) and Pituitary Gland Connection

Sudden cardiac death (SCD) is death resulting from unexpected cessation of cardiac activity within one hour of the onset of disease symptoms. It remains one of the leading causes of death worldwide and continues to be one of the most complex and pressing problems in medicine, particularly in pathological anatomy and forensic medicine.

The presented study (Imomov X.M. et al.) aims to expand the understanding of the pathomorphological mechanisms of SCD, with particular attention to the state of the pituitary gland (hypophyseal appendage), a central organ of the neuroendocrine system.

Role of the Pituitary Gland in SCD

The pituitary gland plays a crucial role in the body's response to stress, hormonal regulation (particularly through hormones such as cortisol and vasopressin), and blood pressure control. Morphological changes in the pituitary are natural under conditions of chronic stress, ischemia (insufficient blood supply), or hypoxia (oxygen deficiency). These changes, in turn, can lead to myocardial fibrillation and further deterioration of cardiovascular system function.

Relevance of the Study:

To establish precise causes and criteria for SCD, it is necessary to investigate changes in organs beyond the heart. Changes in the pituitary may reflect alterations in humoral regulation resulting from chronic hypoxia or sympathetic denervation, which in turn increases the risk of SCD.

Purpose

The objective of the study: **To investigate pathomorphological changes in the pituitary gland in sudden cardiac death (18–59 age groups) using silver nitrate ($AgNO_3$) impregnation.**

Materials, Methods, and Basics of Pituitary Histology

Materials and Methods

The study was conducted on pituitary tissues from individuals who died suddenly from cardiac causes (age groups 18–44 and 45–59) examined at the forensic medical expertise center of the Andijan branch between 2015 and 2024.

Silver Nitrate ($AgNO_3$) Impregnation

Silver nitrate impregnation is a widely used histological method to clearly visualize reticular fibers (type III collagen) and basal membranes.

Reticular fibers: These are thin, branched collagen fibers that form the stromal framework of endocrine glands (e.g., pituitary), liver, and lymphoid organs. They create a delicate network supporting tissue cells.

ORIGINAL ARTICLE
INTERNATIONAL JOURNAL OF ARTIFICIAL INTELLIGENCE
ISSN: 2692-515-x, Impact Factor: 9.23
American Academic publishers, volume 6, issue 01,2026
Journal: https://www.academicpublishers.org/journals/index.php/ijai

1. **Impregnation mechanism**: Silver ions bind to reducing groups in the fibers, forming black or brown precipitates, making them much more contrasty compared to conventional staining methods. This is particularly important for assessing the degree of fibrosis (connective tissue proliferation).

Basics of Pituitary Histology

The pituitary gland consists of two main parts:

- **Adenohypophysis (anterior lobe)**: Composed of hormone-producing cells (parenchyma) and supporting connective tissue (stroma). Adenohypophysis cells are divided into the following types:
  - Basophil cells: Produce various tropic hormones (TSH, ACTH, FSH, LH); typically stain blue-violet in histological preparations.
  - Acidophil (or eosinophil) cells: Produce growth hormone (GH) and prolactin (PRL); typically stain pink-red.
  - Chromophobe cells: Stain weakly, with low hormonal activity.
- **Neurohypophysis (posterior lobe)**: Mainly consists of nerve fibers from the hypothalamus and supporting pituicytes.

The study focused primarily on changes in the stroma and parenchyma of the adenohypophysis.

Results and Discussion

The study results revealed significant pathomorphological changes in the pituitary gland of individuals who died from SCD, specific to the age groups. These changes primarily concern fibrosis (connective tissue proliferation) and the state of hormone-producing parenchymal cells.

Results for the 18–44 Age Group (Figures 1 and 2)

In this relatively young group, the following main changes were identified:

- **Thickening of the basal membrane:** The basal membrane surrounding parenchymal cells was clearly thickened.
- **Enhanced contrast of reticular fibers:** Silver nitrate impregnation highlighted reticular fibers with high contrast, indicating the onset or intensification of fibrotic processes.
- **Reduction in basophil cells:** A decrease in the number of hormone-producing basophil cells was observed, which may negatively affect pituitary hormonal function.
- **Edema:** Perivascular (around blood vessels) and interstitial (between tissues) edema was present, indicating circulatory disturbances or inflammatory processes.

1,2-figures

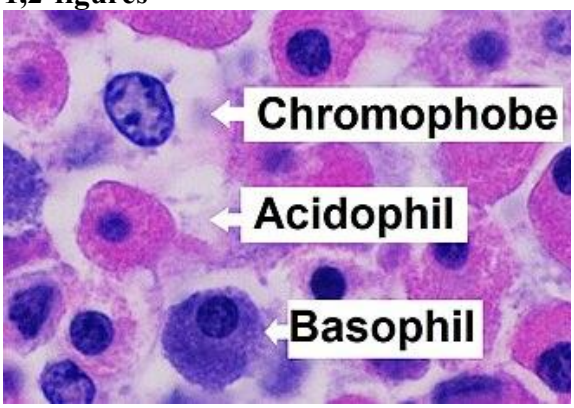

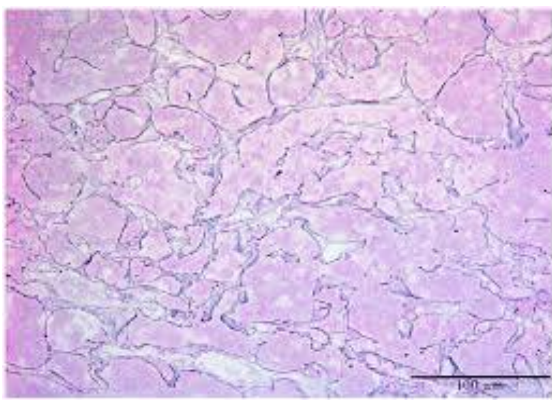

ORIGINAL ARTICLE
INTERNATIONAL JOURNAL OF ARTIFICIAL INTELLIGENCE
ISSN: 2692-515-x, Impact Factor: 9.23
American Academic publishers, volume 6, issue 01,2026
Journal: https://www.academicpublishers.org/journals/index.php/ijai

Analysis

Changes in this age group (reduction in basophils, enhanced reticular fibers) may be associated with rapidly developing pathological processes, possibly due to the young organism's strong stress response to acute or subacute hypoxia or early stages of ischemic heart disease.

Results for the 45–59 Age Group

In the older age group, changes were more pronounced:

- **Coarse collagen fibers and septa:** Coarse collagen fibers and linear septal formations reflecting age-related fibrotic processes were identified in the pituitary stroma. Coarsening of collagen fibers (transition from type III to type I) indicates chronic fibrosis.
- **Coarsening of reticular fibers:** Compared to the younger group, reticular fibers were not only contrasty but also coarsened (thickened).
- **Changes around acidophil cells:** Coarsening of reticular fibers was particularly prominent at the borders of acidophil cells (GH and PRL producers).
- **Interstitial edema:** Interstitial edema was also observed in this group.

Analysis

Changes in this group result from the combination of age-related morphological processes (natural fibrosis) and long-term ischemic heart disease or chronic circulatory disturbances. Coarse fibrosis (collagen) may mechanically restrict the pituitary's hormone-producing capacity.

Conclusion, Discussion, and International Context

Conclusion

The main conclusion of the study is that in sudden cardiac death cases in the 18–59 age groups, age-dependent and pathological fibrotic changes are observed in the pituitary gland.

Key changes:

1. **Fibrosis:** Thickening of reticular fibers and basal membranes (contrasty in younger individuals, coarse collagen fibers in older ones) confirms the presence of fibrotic processes in the pituitary stroma due to chronic hypoxia and hemodynamic disturbances.
2. **Cellular changes:** Reduction in basophil cells may indicate disruptions in the regulation of stress-response hormones (ACTH, TSH).

Discussion and International Sources

The findings indicate that changes in the pituitary gland are related to cardiac pathologies, particularly SCD.

- **Hypoxia and Pituitary:** According to international sources (e.g., journals "Endocrinology" and "Cardiovascular Pathology"), chronic systemic hypoxia (e.g., in chronic heart failure) can lead to proliferation of pituicytes (support cells in neurohypophysis) and the reticular network in the adenohypophysis. These changes reflect impaired adaptive mechanisms preceding SCD.
- **Basophil Cells and Stress:** Corticotroph basophil cells produce adrenocorticotropic hormone (ACTH), which regulates the body's stress response. Reduction in basophil cells may be linked to exhaustion of the hypothalamic-pituitary-adrenal axis due to chronic stress (cardiac ischemia).
- **Fibrosis and Aging:** Pituitary fibrosis (coarsening of reticular fibers) is partly a natural aging process (45–59 age group), but in SCD cases, this process is pathologically accelerated. The study reveals age-specific features of the pathological process (basophil reduction in younger individuals, coarse fibrosis in older ones).

ISSN: 2692-515-x, Impact Factor: 9.23
American Academic publishers, volume 6, issue 01,2026
Journal: https://www.academicpublishers.org/journals/index.php/ijai

Directions for Future Research: Additional immunohistochemical studies are needed to investigate how these pituitary changes directly influence cardiac arrhythmic mechanisms leading to SCD (e.g., via alterations in catecholamine levels).

References

1. Бойцов С.А., Никулина Н.Н., Якушин С.С. и др. Внезапная сердечная смерть у больных ИБС: распространенность, выявляемость и проблемы статистического учета. Российский кардиологический журнал. 2011;2:59-64.
2. Бокерия О.Л., Биниашвили М.Б. Внезапная сердечная смерть и ишемическая болезнь сердца. Анналы аритмологии. 2013;10(2):69-79.doi: 10.15275/annaritmol.2013.2.2
3. Болезни сердца и сосудов: руководство Европейского общества кардиологов: пер. с англ. Под ред. Кэмма А.Д., Люшера Т.Ф., Серруиса П. В. М.: ГЭОТАР-Медиа 2011.
4. Мазур Н.А. Внезапная сердечная смерть. Рекомендации Европейского Кардиологического общества. М.: Медпрактика-М. 2003.
5. Неханевич О.Б., Войченко В.В. Анализ случаев внезапной сердечной смерти среди лиц молодого возраста в Днепропетровской области. Морфологія. 2013;7:2:61-65
6. Халиков А.А. и др. Судебно-медицинские аспекты внезапной аутопсия-отрицательной сердечной смерти. Судебно-медицинская экспертиза 2021, №3 с. 59–63
7. Хакимов З.К. Роль гипоталамо-гипофизарной системы в внезапной коронарной смерти. Экономика и социум" №11(102)-1 2022 www.iupr.ru 961-964с.
8. Myerburg RJ, Junttila MJ. Sudden cardiac death caused by coronary heart disease. Circulation. 2012;125:1043-52.